



Available online at <http://www.harmanpublications.com>

World Journal of Science and Research

Harman Publications. All rights reserved



Research Article

Zoology

HISTOLOGICAL OBSERVATION IN THE DIFFERENT TISUSES OF *Octopus aegina*

S. Kavitha¹, and Dr. A. Christy Ponni^{2*}

¹ Research scholar P.G and Research Department of Zoology, TBML College, Porayar - 609 307, Tamil Nadu, India.

² Head of the Department, P.G and Research Department of Zoology, TBML College, Porayar - 609 307, Tamil Nadu, India.

ABSTRACT

Octopus aegina is an important species in Tamil Nadu coastal region having good nutritional values. In the present study, the histological investigation of the different tissues (Gills, liver, muscles, gonad and ovary) of *Octopus aegina* collected from Pazhayar, Kollidam Taluk, Nagapattinam District, Tamil Nadu India. The present work on histological observation was carried out in gills, liver, muscles, gonad and ovary that had resulted from marine *Octopus aegina*.

Key words : Histology, *Octopus aegina*, Gills, Liver, Muscles, Gonad and Ovary.

Citation: S. Kavith1, and Dr. A. Christy Ponni. (2017) Histological observation in the different tisuses of *Octopus aegina*, *World Journal of Science and Research*. 2(4): 14-17

Article Info:

Received on 1st Oct 2017
Accepted on 28th
December. 2017
Online December 2017

Keywords:

Histological
Octopus aegina,
Pazhayar

*Corresponding author

Dr. A. Christy Ponni, Head of the Department, P.G and Research Department of Zoology, TBML College, Porayar - 609 307, Tamil Nadu, India.

INTRODUCTION

Octopods represent a major protein resource in most seafood consumer countries (FAO, 2002). The best known species, the common octopus *Octopus aegina*, is the most important commercial species and is a serious candidate to be

a new aquaculture product (García and Aguado, 2002). In recent years the study of the octopus has increased due to its high economic value and potentiality of its culture, because they are short-lived organisms with high growth rates (Iglesias and Sanchez, 2007). In addition, they are an

important source of food for human consumption with high protein content (75 to 85% of the dry weight of its body composition), approximately 20% more compared with the fish (Lee, 1994). In relation to the research of the histology of these organisms, few species have been studied and this information is necessary for the fishery resources management and the aquaculture development.

The cephalopod capture is an artisanal fishery along the coast that does not have a precise regulation of their populations and catches (Boyle and Rodhouse, 2005). The presence and taxonomic identification of the genus *Aggregata* in cephalopods have been recorded by different authors (Dobell, 1925; Narasimhamurti, 1979; Sardella and Re, 1988; Estévez *et al.*, 1996; Gestal *et al.*, 1999). Observations on associated pathology of *Aggregata* infections in cephalopods is limited to *A. dobelli* and *A. millerorum* parasites of *Octopus dofleini* and *O. bimaculoides* respectively (Poynton *et al.*, 1992).

MATERIALS AND METHODS

The *Octopus* were collected from Pazhayar area, Nagapattinam District, south east coast Tamil Nadu and were brought to the laboratory in large plastic troughs and acclimatized for one week. Healthy *Octopus* were sacrificed and liver, gill, muscles, gonad and ovary tissues were dissected, removed and fixed in 10% formalin on the spot. After 24 hours the fixed tissues were taken for histological technique followed by Gurr (1959). For histological analysis section were cut at 5-6µm thickness and stained with Haematoxylin and

Eosin. After stained the slides were examined under light microscope and photographed (Labomed).

RESULTS

In the present investigation, the gill tissue of *Octopus aegina* primary gill lamella, secondary gill lamella, gill filaments and squamous epithelial cells were observed (Fig.1). The cellular components included numerous hepatic cells (Parenchyma cells). The hepatocytes are polygonal having a distinctive centrally placed nucleus. Sinusoids or liver capillaries are irregularly distributed between the polygonal hepatocytes being fewer in number forming a cord like structure were noted (Fig.2). The normal structure was observed in the *Octopus aegina* of muscle tissue. The microscopic examination of the muscles showed normal appearance of the tissue where, smooth cell appear, endomysium and cell nuclei were noted (Fig.3). The gonad tissues of *Octopus aegina*, the normal structure of spermatogonia and sperm cells were observed (Fig.3). The membrane that surrounds the ovary is a fibrous tissue, mainly collagen. This membrane emerges projections or trabeculae of fibrous tissue in the form of branches within the ovary, where the germ cells and developing oocytes forms the ovarian stroma. The distal and proximal oviducts have smooth muscle fibers, fusiform and parallel to each other, with elongated central core. The lumen of the oviduct epithelium consists of ciliated cells were observed (Fig. 5). The present work on histological observation was carried out in gills, liver, muscles, gonad and ovary that had resulted from marine *Octopus aegina*.

Fig. 1. Structure of gill in the marine *Octopus aegina* (40x).

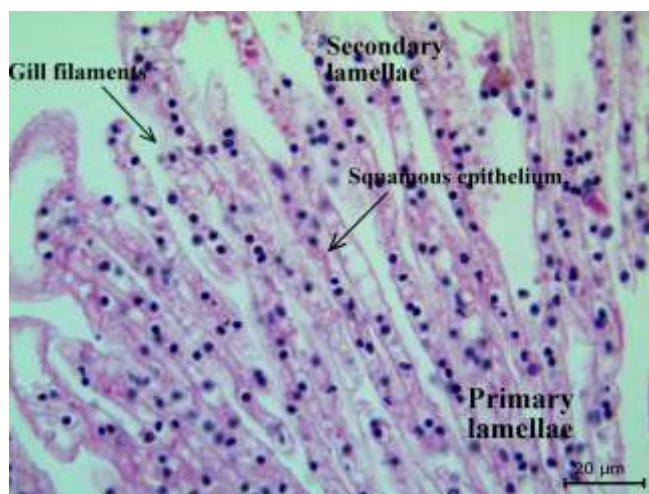


Fig. 2. Structure of liver tissue in the marine the *Octopus aegina* (40x).

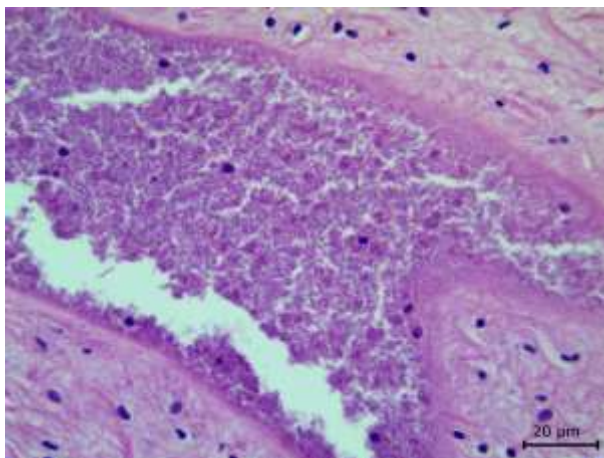


Fig. 3. Structure of muscles tissue in marine *Octopus aegina* (40x).

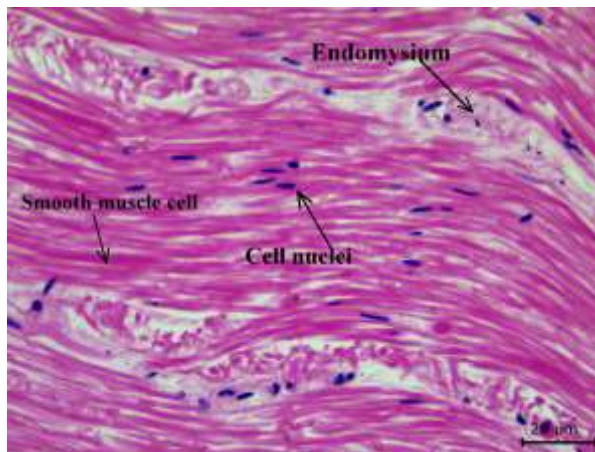


Fig. 4. Structure of gonad tissue in the marine *Octopus aegina* (40x)

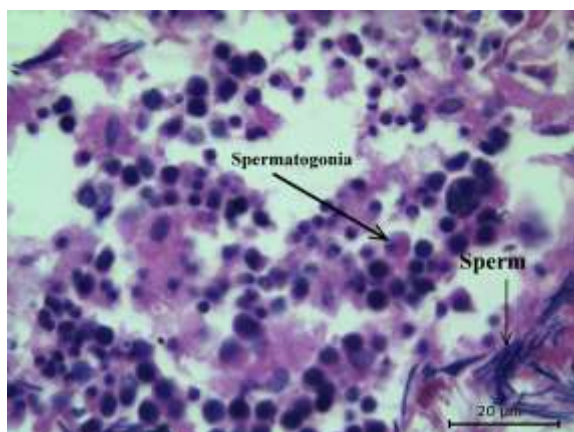
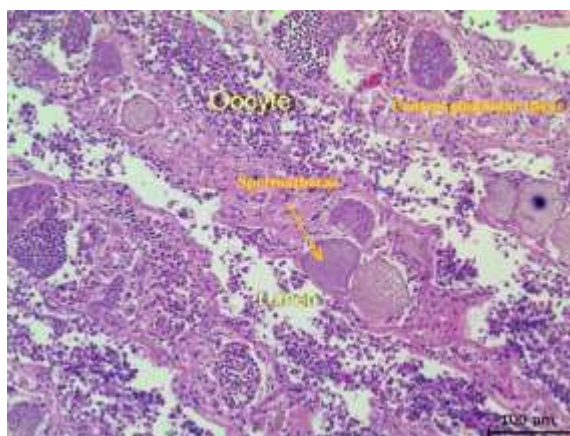


Fig. 5. Structure of ovary tissue in the marine *Octopus aegina* (40x).



DISCUSSION

Histological analysis of the anatomy of the reproductive system of the octopus can explain the maturation process of gametes and precisely define the stage of gonad maturity. The ovary of *O. rubescens* is similar to *O. bimaculoides*, *O. mimus* and *O. vulgaris* (Jiménez-Badillo *et al.*, 2008). Staining techniques used in this research, did not allow identifying the types of substances secreted in the oviductal gland tissues. However, Froesch and Marthy (1975) and Grubert and Wadley (2000) were able to identify through conventional staining methods, the secretion of a mucoprotein in the peripheral tissue of the oviductal gland which serves to fix the eggs to the substrate, while the central region secretes a mucopolysaccharide that polymerizes the mucoprotein (Boyle and Rodhouse, 2005).

The oocyte maturation process is very similar in female cephalopods. The distinctive and peculiarity in the oogenesis of these species, is the formation of a second layer of follicular cells and the follicular invagination, which generate the yolk secretion (Boyle and Knobloch, 1984). Although there is much discrepancy in the number of stages established and nomenclature assigned, most studies agree on a stage for the secondary follicle formation, and subsequently the formation of the chorion (Boyle and Knobloch, 1984; Arkhipkin, 1992; Gabr *et al.*, 1998; Jiménez-Badillo *et al.*, 2008).

Molluscs have both cellular and humoral mechanisms of defense (Ford, 1992). The most widely reported defense mechanism in cephalopods is the cellular one (Malham, 1996; Malham and Runham, 1998). This paper provides a detailed description of the microscopic structure of the gill,

liver, muscles, gonad and ovary in the marine *Octopus aegina*. In addition we propose a simple microscopic scale that can be used to determine the maturity degree of the organisms, which can be used in subsequent investigations.

CONCLUSION

The present investigation, the histological observation in different tissues gill, liver, muscles, gonad and ovary in the marine *Octopus aegina*. Thus, it can be concluded that the present work on histological observation was carried out in gills, liver, muscles, gonad and ovary that had resulted from marine *Octopus aegina*.

Acknowledgements

Author is grateful thanks to the Principal and other staff members of Zoology, TBML College, Poraiyar, Tamil Nadu, India for providing necessary facilities.

References

Arkhipkin, A. T., 1992 Reproductive system structure, development and function in cephalopods with a new general scale for maturity stages. *J. Northwest Atl. Fish. Sci.*, 12: 63 - 74.

Boyle, P. R., and Knobloch, D., 1984. Male reproductive maturity in the octopus, *Eledone cirrhosa* (Cephalopoda: Octopoda). *J. Mar. Biol. Ass. U. K.*, 64(3):573 - 9.

Boyle, P. R., and Rodhouse, P., 2005. *Cephalopods. Ecology and Fisheries*. Oxford, Blackwell, p.452.

Dobell, C.C., 1925. The life-history and chromosome cycle of *Aggregata eberthi* (Protozoa: Sporozoa: Coccidia). *Parasitol.*, 17:1 - 136.

Estevez ,J., Pascual, S., Gestal, C., Soto, M., Rodríguez, H., and Arias, C., 1996. *Aggregata octopiana* (Apicomplexa: Aggregatidae) from *Octopus vulgaris* off NW Spain. *Dis. Aquat. Org.* 27: 227 -231.

FAO., 2002. Yearbook. Fishery Statistics, vol. 94/1. FAO, Rome.

Ford, L., 1992. Host defense mechanisms of cephalopods. *Annu. Rev. Fish Dis.*, 1: 25 - 41.

Froesch, D. and Marthy, H. J., 1975. The structure and function of the oviducal gland in octopods (Cephalopoda). *Proc. R. Soc. Lond. B*, 188: 95 - 110.

Gabr, H. R., Hanlon, R. T., Hanafy, M. H., and El-Etreby, S. G., 1998. Maturation, fecundity and seasonality of reproduction of two commercially valuable cuttlefish *Sepia pharaonis* and *S. dollfusi*, in the Suez Canal. *Fish. Res.*, 36(2-3): 99 - 115.

García, B., and Aguado, F., 2002. Influence of diet on on-growing and nutrient utilization in the common octopus (*Octopus vulgaris*). *Aquacult.*, 211: 171 - 182.

Gestal, C., Pascual, S., Corral, L., and Azevedo, C., 1999. Ultrastructural aspects of the sporogony of *Aggregata octopiana*, a coccidian parasite of *Octopus vulgaris* (Mollusca, Cephalopoda) from NE Atlantic Coast. *Eur. J. Protistol.*, 35: 417 - 425.

Grubert, M. A., and Wadley, V. A. 2000. Sexual maturity and fecundity of *Octopus maorum* in Southeast Tasmania. *Bull. Mar. Sci.* 66(1): 131 - 42.

Gurr, E., 1959. *Methods of analytical Histology and Histochemistry*. Leonard Hill Ltd., London, pp. 45-49.

Iglesias, J., and Sánchez, F. J., 2007. *La diversificación en moluscos cefalópodos: El pulpo (Octopus vulgaris)*. Sesión Temática Diversificación. IX Congreso de Acuicultura, Vigo, España.

Jiménez-Badillo, M. L., Del Río-Rodríguez, R. E., Gómez-Solano, M. I., Cu-Escamilla, A., and Méndez-Aguilar, D., 2008. *Madurez gonádica del pulpo Octopus vulgaris en el Golfo de México: análisis microscópico*. Universidad Autónoma de Campeche, p.48.

Lee, P. G., 1994. Nutrition of cephalopods: fueling the system. *Mar. Fresh. Behav. Physiol.*, 25: 35-51.

Malham, S.K., 1996. Immunobiology of *Eledone cirrhosa* (Lamarck) PhD thesis, University of Wales, Bangor.

Malham, S.K., Runham, N.W., 1998. Cephalopod biodiversity, ecology and evolution. *South Afr. J. Mar. Sci.*, 20: 385 – 391.

Narasimhamurti, C.C., 1979. The eimeriid *Aggregata kudoin* sp. from *Sepia eliptica*. *Angew. Parasitol.*, 20: 154 – 158.

Poynton, S., Reimschuessel, R., and Stoskopf, K., 1992. *Aggregata dobelli* n. sp. and *Aggregata millerorum* n. sp. (Apicomplexa: Aggregatidae) from two species of octopus (Mollusca: Octopodidae) from the Eastern North Pacific Ocean. *J. Protozool.* 39: 248 - 256.

Sardella, N., and Re, E., 1988. Parasitosis por coccidios del género *Aggregata* en pulpos costeros patagónicos. 1. *Aggregata* sp. en *Octopus tehuelchus* D'orbigny. *Physis. Secc. A. Oceanos. Org.*, 46(111): 51 - 60.

Source of support: Nil;

Conflict of interest: None declared